



PATIENT

Toruk Oseguera

SPECIES

Canine

BREED

Dogue de Bordeaux

SEX

Male

AGE

4 years

WEIGHT

126lbs

INTERPRETED BY

Maggie Machen Lamy,
DVM, DACVIM
(Cardiology)

IMAGING PERFORMED BY

Arun Kutagulla, DVM

HOSPITAL NAME

Union Park Animal
Hospital

REFERRING VET

Dr. Arun Kutagulla

INVOICE

47748

DATE

5/9/26

PRESENTING CLINICAL SIGNS

History: Arrythmia. Heart murmur and less audible heart sounds on PE 3/2025. Has been losing weight despite eating lot of food. Increased resting respiratory rate noted during nighttime.

Abnormal PE/Chem/CBC/UA Results: Mildly elevated WBC and neutrophils, proteinuria 3+ otherwise unremarkable bloodwork (normal chemistry,T4) 3/2026. Positive for hookworms.

ELECTROCARDIOGRAPHIC FINDINGS *Note: Single lead ECGs are evaluated as a rhythm strip. Morphology/MEA cannot be definitively commented on.

A single lead ECG is attached to the echo machine. Measurements cannot be made; however, the irregular rhythm and increased HR with no identifiable P waves is most consistent with atrial fibrillation.

ECHOCARDIOGRAM FINDINGS

Limited 2D, m-mode and color flow imaging is available. Severe left ventricular dilation with depressed systolic function. Decreased LV wall thickness and increased sphericity. Severe left atrial enlargement. The mitral valve appears mildly thickened with no obvious prolapse into the left atrial lumen. Mild to moderate mitral regurgitation. The tricuspid valve appears mildly thickened with mild TR. Moderate right atrial and ventricular dilation. Scant pericardial effusion. Pockets of pleural effusion noted. No obvious cardiac tumors.

CARDIAC CHART

CANINE CARDIAC PARAMETERS	MR VMAX (m/s)	TR VMAX (m/s)	LA/AO (Boon method)	LA/AO (Heart Base; Swe)	FS (%)	EF (%)	EPSS (cm)
NORMAL PARAMETER	4.5-5.5	<2.7	1.3	<1.6	28-40	40-100	<0.6
PATIENT	NM	NM	NM	2.2	14	24	NM
CANINE CARDIAC PARAMETERS	HR (BPM)	AV VMAX (m/s)	PV MAX (m/s)	BODY WEIGHT (kg)	LA 2D short axis Base view (cm)	LVIDd Avg; 2D and m-mode short axis (cm)	LVIDs Avg; 2D and m-mode short axis (cm)
NORMAL PARAMETER	50-100	0.7-1.7	0.7-1.6	BELOW	BELOW	BELOW	BELOW
PATIENT	NM	NM	NM	57.2	5.4	5.7	4.9
*Normal chamber parameters expressed as a mean value (SD)				3	1.27 (5.3)	2.46 (2.46)	1.36 (5.5)
BODY WEIGHT DEPENDENT PARAMETERS				5	1.40 (4.5)	2.74 (5.2)	1.60 (4.7)
*Note: All measurements based upon multi-modal images and methods. An average value is reported.				10	1.50 (3.8)	3.27 (3.5)	2.06 (3.1)
				15	1.83 (2.0)	3.71 (2.4)	2.43 (2.1)
				20	2.02 (1.9)	4.14 (2.2)	2.80 (2.0)
				25	2.18 (2.4)	4.48 (2.9)	3.10 (2.5)
				30	2.33 (3.3)	4.83 (3.9)	3.39 (3.4)
				35	2.48 (4.3)	5.17 (5.0)	3.69 (4.5)
				40	2.62 (5.2)	5.48 (6.1)	3.96 (5.4)
				50	2.88 (7.1)	6.07 (8.3)	4.46 (7.4)

Adapted from June Boon, Veterinary Echocardiography, 1998
 Rishniw M and Hollis NE, J Vet Intern Med 2000; 14:429-435
 Hansson et al, Vet Rad and Ultrasound 2002
 Bonagura et al. Echocardiography: principles of interpretation, Vet Clin North Am 15:1177, 1995



PATIENT

Toruk Oseguera

SPECIES

Canine

BREED

Dogue de Bordeaux

SEX

Male

AGE

4 years

WEIGHT

126lbs

INTERPRETED BY

Maggie Machen Lamy,
DVM, DACVIM
(Cardiology)

IMAGING PERFORMED BY

Arun Kutagulla, DVM

HOSPITAL NAME

Union Park Animal
Hospital

REFERRING VET

Dr. Arun Kutagulla

INVOICE

47748

DATE

5/9/26

INTERPRETATION OF THE FINDINGS & FURTHER RECOMMENDATIONS

Limited image set provided. What can be said is there is significant cardiomyopathy and systolic dysfunction, with dilation and overload of all 4 chambers resulting in insufficiency of the mitral and tricuspid valves. There is severe LA and LV dilation indicating high risk for complication going forward. No additional issues are identified; however, without a complete image set, additional issues such as pulmonary hypertension cannot ruled out.

Systolic failure can be primary in nature (DCM) or secondary to taurine deficiency, myocarditis, tachycardia-induced cardiomyopathy, or infiltrative disease such as lymphoma. In a large breed dog, primary disease is certainly a possibility; however, a thyroid and taurine level can be assessed, with avoidance of grain free, exotic ingredient or boutique brand options going forward.

As a complicating factor, the patient has also developed rapid atrial fibrillation (AF) secondary to atrial dilation. Development of the arrhythmia puts the patient at high risk for acute decompensation and development of right-sided congestion (tricuspid effusion in this case). AF is characterized by disorganized contractions of the atria leading to an irregular heart rhythm. The irregular heart rhythm rarely causes clinical signs in dogs. However, atrial fibrillation also usually causes an increase in the heart rate, and this can lead to clinical signs and CHF as we see in this patient. Once a patient is in AF, this will likely never convert back to sinus rhythm; however, they typically do well with simply rate control. The structural disease and development of AF requires lifelong diuretics and management of the structural disease in addition to the arrhythmia as below. Close monitoring going forward is advised.

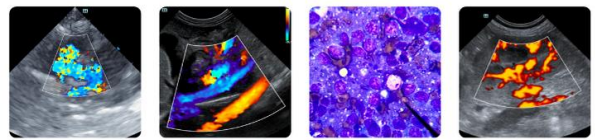
Regardless of cause, prognosis is guarded to poor at this stage in the disease process, with an average survival time of <6 months. Patient will always be at risk for recurrent CHF, development of malignant arrhythmias and/or sudden death in the future. The only treatable cause of systolic failure is taurine deficiency, which is uncommon on commercially formulated dog foods (albeit renewed with the recent correlation to grain free diets). If a taurine level is declined, it is also reasonable to simply supplement with taurine on the off chance of a malabsorption issue.

Monitoring of sleeping respiratory rates will be paramount to screen for recurrent congestive heart failure at home in the future. Cough suppression to improve QOL can also be considered once diuretics are on board for any residual mechanical cough in the face of normal sleeping respiratory rates.

Monitor for development of a cough, labored breathing, exercise intolerance or collapse episodes in the future. Omega fatty acid supplementation (1000mg once to twice daily) and mild salt restriction may be of some long-term benefit.

PLAN:

If the patient appears unstable, recommend referral for 24-hour monitoring/supportive care and IV rate control/diuretics. Recommend the following oral medications: Pimobendan 0.3mg/kg PO q12h, Lasix 1-2mg/kg PO q12h; Spironolactone 1-2mg/kg PO q12h; Diltiazem 1-2mg/kg PO q8h.



PATIENT

Toruk Oseguera

SPECIES

Canine

BREED

Dogue de Bordeaux

SEX

Male

AGE

4 years

WEIGHT

126lbs

INTERPRETED BY

Maggie Machen Lamy,
DVM, DACVIM
(Cardiology)

IMAGING PERFORMED BY

Arun Kutagulla, DVM

HOSPITAL NAME

Union Park Animal
Hospital

REFERRING VET

Dr. Arun Kutagulla

INVOICE

47748

DATE

5/9/26

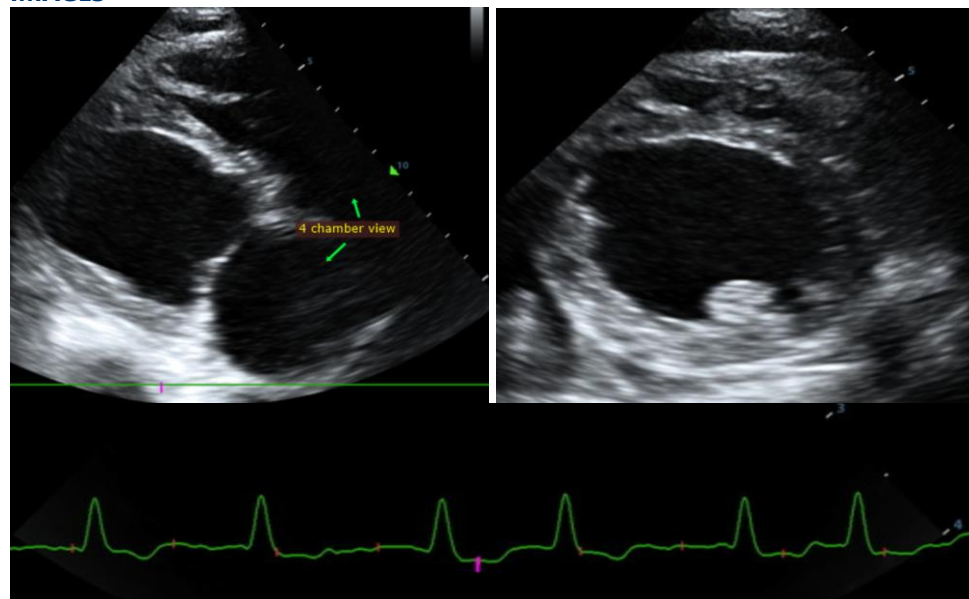
Institute taurine supplement 1000-2000mg PO q12h. Consider diet history, taurine level, etc. as discussed.

Recheck BP, heart rate/ECG and renal values in 5-7 days. If BP > 130mmHg and patient is feeling well, institute Benazepril at that time (0.5mg/kg PO q12h). Target HR is 140-160bpm in hospital/stressed. Up-titrate diltiazem to effect. If difficult to control, can also consider digoxin (0.005mg/kg PO q12h with close monitoring of blood dig levels) due to synergistic effect with diltiazem.

Monitor renal values/BP/HR every 3-4 months lifelong.

A recheck echocardiogram is recommended in 4-6 months to screen for progression.

IMAGES



The information and recommendations provided are based on the images presented by the referring veterinarian. No evaluation can be communicated regarding pathology that was not visible in the image/video clips provided.

Thank you for this referral. This report was generated using transcription software, and minor dictation errors may be present. If the clinical or image interpretation does not parallel your findings or if I can be of any further assistance, please contact me.

Maggie Machen Lamy, DVM
Diplomate of the American College of Veterinary Internal Medicine (Cardiology)
info@sonopath.com